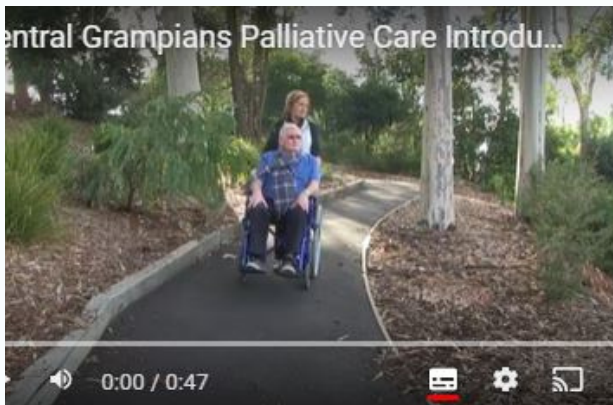

RESOURCES FOR PATIENTS AND FAMILIES

HOME CARE RESOURCES

This is a useful collection of links to home care resources.

GENERAL RESOURCES

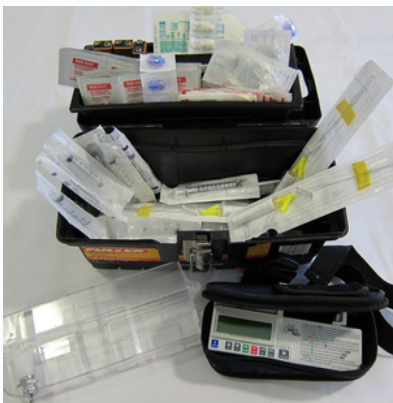

Palliative care YouTube channel by an Australian aged care and Hospice facility, with many practical instruction videos



Carers NZ website, with a broad range of information in both written and video formats specific to New Zealand

SYRINGE DRIVER AND SUBCUTS



Setting up a syringe driver



Connecting a loaded syringe driver

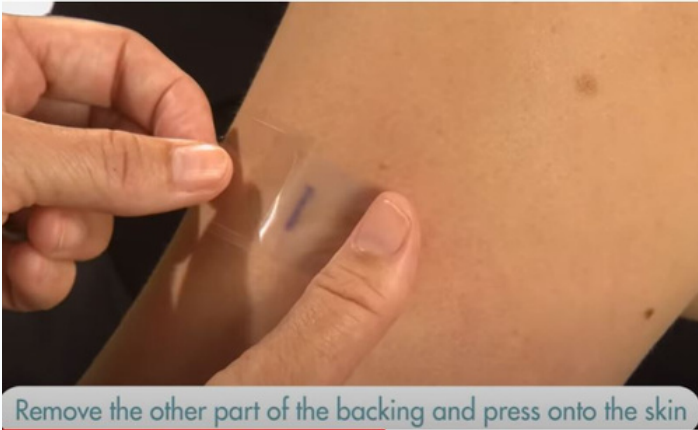

Inserting a subcutaneous line

RESOURCES FOR PATIENTS AND FAMILIES

HOME CARE RESOURCES

FENTANYL PATCHES

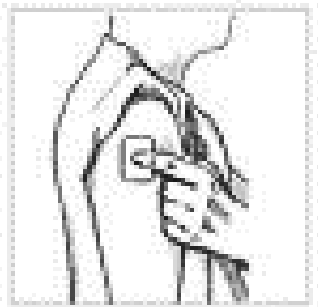
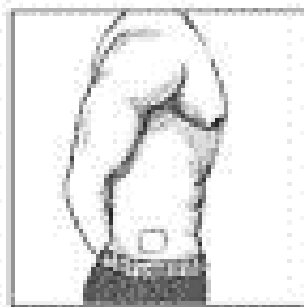

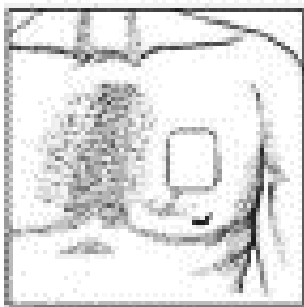


Watch:

Clear instructions on how to apply, remove and dispose of Fentanyl patches.

How to Apply Your Fentanyl Patch

1. Remove the old patch(es) first
2. Write the day of application on the outside of the new patch(es)
3. Peel the plastic backing off and apply the new patch(es) to dry, clean, non-irritated area of flat skin where there is not too much hair. Common sites include:



How to Dispose of Fentanyl Patch

Some Fentanyl may be on the patch so make sure to keep this out of reach of children.

Carefully remove the patch and fold the sticky side of the patch together. Wrap the patch and place into rubbish bin.

If you have questions about using a Fentanyl patch, please contact your prescriber or Hospice West Auckland on 0800 834 9755.

RESOURCES FOR PATIENTS AND FAMILIES

HOME CARE RESOURCES

MOVING AND HANDLING



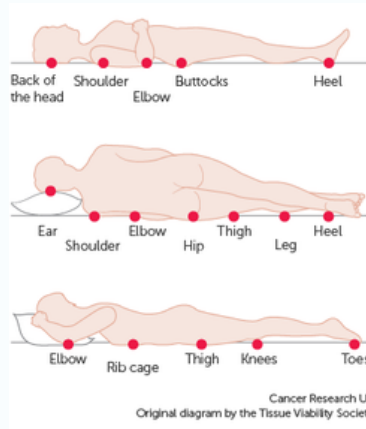
On a sideline, these sorts of movements take a lot of pressure off your back.



On a sideline, these sorts of movements take a lot of pressure off your back.

Using slide sheets in bed

Carers manual handling guide



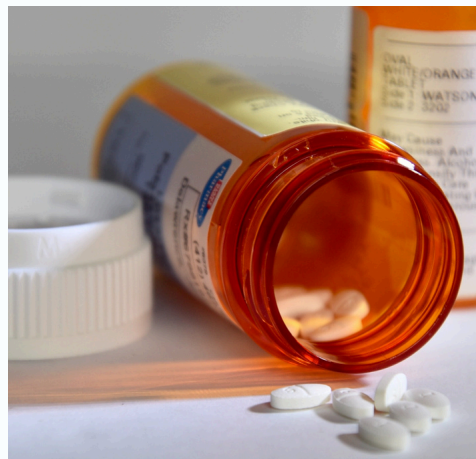Pressure area basic information

CLASSIFY AND DOCUMENT PRESSURE INJURY

<p>with non-blanchable redness of a localized area over a bony prominence.</p> <p>Intact skin may not have visible blanching; its color may differ from the surrounding area.</p> <p>It may be painful, firm, soft, warmer or cooler than adjacent tissue.</p> <p>Difficult to detect in individuals with dark skin tones.</p> <p>"at risk" persons (a heralding sign of risk).</p>	<p>Stage 2</p> <ul style="list-style-type: none"> - Partial thickness loss of dermis presenting as a shallow ulcer with a red-pink wound bed, without slough or eschar. - May also present as an intact or open/rupture filled blister. - Presents as a shiny or dry, shallow ulcer with a white or yellow fibrinous base. - Stage 2 pressure injuries (PI) should not be confused with skin tears, tape burns, perineal dermatitis, or excoriations.
<p>Full thickness tissue loss with exposed bone, tendon or cartilage or eschar may be present on some parts of the body.</p> <p>Stage 4 PI can extend into muscle and/or bone (e.g. fascia, tendon or joint capsule) if osteomyelitis is possible. Exposed bone or tendon is not palpable.</p>	<p>Unstageable</p> <ul style="list-style-type: none"> - Full thickness tissue loss in which the base of the ulcer is covered by slough (yellow, tan, grey, green or brown) or eschar (tan, brown or black) in the PI bed. - Until enough slough/eschar is removed to expose the PI, the true depth, and therefore the stage, cannot be determined. Stable (dry, adherent, intact without fluctuant) eschar on the heels serves as its natural biological cover and should not be routinely debrided.

In-depth pressure area information, including multilingual pamphlets

MEDICATION



DEATH AND DYING



CONTINENCE VIDEO SERIES

